

Application of J-Plasma in the excision of diaphragmatic lesions as part of complete cytoreduction in patients with advanced ovarian cancer

VASILIOS THEODOULIDIS¹, ANASTASIA PRODROMIDOU¹, EMMANOUIL STAMATAKIS²,
NICHOLAS ALEXAKIS³, ALEXANDROS RODOLAKIS¹ and DIMITRIOS HAIDOPOULOS¹

¹First Department of Obstetrics and Gynecology, Gynecological Oncology Unit, National and Kapodistrian University of Athens; ²Department of Anesthesiology and Pain Management, 'Alexandra' General Hospital, 11528 Athens; ³First Department of Propaedeutic Surgery, Hippocratio Hospital, National and Kapodistrian University of Athens, 11527 Athens, Greece

Received February 28, 2022; Accepted April 15, 2022

DOI: 10.3892/mco.2022.2546

Abstract. For the resection of diaphragmatic disease in patients with advanced ovarian cancer (OC), a plethora of ablative methods have been utilized. The present study aimed to present preliminary data on the use of J-Plasma in OC with diaphragmatic involvement via a retrospective review of patients who had diaphragmatic stripping with of J-Plasma[®] from January 2016 to September 2020. A total of 12 patients (median age, 65 years) were analyzed. Median operative time was 240 min while median estimated blood loss was 400 ml. Median operative time for diaphragmatic resection was 25 min. During a median follow-up of 12 months, two recurrences were noted while none of the patients died of the disease. Median disease free survival was 12 months. Overall, the preliminary outcomes of the present study indicated that J-Plasma could be safely used in diaphragmatic resection and it was associated with low rates of short-term morbidity. However, further studies are warranted to reach to safe conclusions.

Introduction

Epithelial ovarian cancer (OC) is the 2nd most prevalent malignancy of the gynecological tract and the 5th leading cause of death in women (1). A significant proportion (70%) of the patients with epithelial OC, are diagnosed with advanced stage disease mainly due to the lack of specific

symptomatology keeping the cure rates, even with advances in modern treatment, at a low stage (2). A proportion of as high as 70% of patients will be presented with disease relapse within the first 2 years of diagnosis even after optimal treatment (3). Recurrence rates also remain elevated for early stages accounting for 20-25% (3). The optimal management of patients with advanced stage OC combines cytoreductive surgery supplemented with platinum-based chemotherapy. The platinum component is usually cisplatin or carboplatin combined with a taxane including paclitaxel or docetaxel and are administered through intravenous route at 3-4 weeks' intervals. A survival benefit on either overall survival or progression free survival has been shown for the patients who are left with no macroscopic residual disease after complete cytoreduction (4,5). The management of recurrences is challenging while second-line chemotherapy has been associated with poor outcomes based on the high chemo-resistance rates (3). For patients with platinum sensitive recurrent disease 6 cycles of platinum-based chemotherapy are recommended (6). For relapses with platinum free interval less than 6 months non platinum based agents have been used including pegylated liposomal doxorubicin, taxol once a week, topotecan or doxorubicin (7). Recently, the development of targeted therapies is now considered of critical importance (3).

Upper abdominal disease is a frequent finding in numerous cases of advanced OC and has been attributed to diffuse peritoneal dissemination (8). Diaphragmatic involvement, especially of the right hemidiaphragm, has been reported at a range of 42 to 71% of the cases (9). Complete resection of the disease recognized in the diaphragm at the time of cytoreduction has been associated with favorable survival outcomes, as it has been shown that recurrent disease often appears as diaphragmatic residual lesions. This fact pinpoints the paramount importance of complete resection of the diaphragmatic disease (8,10). Diaphragmatic stripping is the most prevalent procedure for the resection of diaphragmatic disease whereas full thickness excision is required in cases of additional involvement of the underlying muscle, despite its association with increased perioperative complications (11). A plethora of

Correspondence to: Dr Anastasia Prodromidou, First Department of Obstetrics and Gynecology, Gynecological Oncology Unit, National and Kapodistrian University of Athens, 'Alexandra' General Hospital, Lourou 4-2, 11528 Athens, Greece
E-mail: a.prodromidou@hotmail.com

Key words: epithelial ovarian cancer, cytoreduction, debulking surgery, J-Plasma, diaphragmatic resection

less invasive ablative methods such as argon and helium beam plasma have been utilized for the resection of disseminated peritoneal implants aiming to minimize the risk of postoperative complications related to extensive surgical procedures to affected structures with simultaneous achievement of complete resection of the malignant lesions. We hypothesize that helium gas plasma (J-plasma) could be beneficial for diaphragmatic stripping, tumor plaque removal or for diffuse tumor deposits vaporization, combining the unique properties of cold helium plasma with radiofrequency energy. This device can adjust radiofrequency energy for greater control of tissue effect, enabling thus a higher level of precision and virtually eliminating unintended tissue trauma (12).

The objective of the present study was to present preliminary data concerning the safety and treatment efficacy of J-Plasma in cases of advanced OC with upper abdominal involvement undergoing peritoneal and primarily diaphragmatic resection.

Materials and methods

A retrospective review of a prospectively maintained database of patients who had diaphragmatic stripping with the use of a novel device (J-Plasma® Precise open 150 mm) from January 2016 to September 2020, due to peritoneal dissemination for advanced stage OC (FIGO stage \geq III) was performed. The records of patients with diaphragmatic disease who underwent surgery either primary or interval debulking for the management of their disease, were retrospectively retrieved and analyzed. We excluded from the study patients who did not give informed consent at the time of surgery, those considered unfit for extensive cytoreduction or did not respond to neoadjuvant chemotherapy as well as those diagnosed with ovarian metastasis from another primary tumor. The Institutional Review Board (IRB) of General Hospital 'Alexandra' approved the conduction of the study and access to patient database (no. 800/14-10-2019).

The use of the J-Plasma device was on a pilot trial in the department of surgical oncology of our institution with the intension to evaluate its safety and feasibility. The open surgical approach was followed for all patients according to the strategies adopted by the Gynecologic Oncology Unit of the 1st Department of Obstetrics and Gynecology of General Hospital 'Alexandra'. A full pre-operative work up was performed including CT and/or MRI scans and tumor markers. The procedures performed were individualized according to each case and aimed for complete cytoreduction. In selected cases where peritoneal implants of the bowel and the mesentery were recognized, plasma was used as a means of vaporization. The J-Plasma device was utilized with a pencil grip of 15 cm, set at 75% power at 24 watts and a gas flow of 4 L/ml. The application of J-plasma in the diaphragmatic lesions consisted of full-thickness diaphragmatic resection, diaphragmatic peritoneal excision (Fig. 1A) or ablation of diaphragmatic implants (Fig. 1B). At the completion of partial resection of the diaphragm for full-thickness diaphragmatic disease, a 'bubble test' was performed to evaluate the integrity of the diaphragm that was repaired after the application of the aforementioned technique (13).

Statistical analysis was performed with SPSS v.25.0 statistical software (version 23.0; IBM Corp.). Continuous variables

were interpreted as median and range while categorical variables were assessed in percentages and total number.

Investigated outcomes. Our primary outcomes included overall survival (OS), disease free survival (DFS), recurrence rates, postoperative 30-day mortality and postoperative complications. Additionally, type of surgery, operative time, blood loss and length of hospital stay were also recorded. Data on patients' and disease characteristics included patients' age, BMI, performance status, CA-125, histological type and disease stage as well as presence of ascites and pleural effusion in the patients under evaluation.

Disease staging was made according to International Federation of Gynecology and Obstetrics (FIGO) staging classification for epithelial OC (14). The patients' performance status was evaluated according to the Eastern Cooperative Oncology Group (ECOG) performance status tool (15) while surgical complications were classified according to the 5 grading system in Dindo-Clavien classification (16).

Results

Patient and disease characteristics. A total of 12 patients who underwent diaphragmatic stripping with the use of J-plasma for cytoreduction due to advanced OC were included. Median patients age was 65 years (range: 45-75 years) and median BMI was 27 kg/m² (range: 23-32 kg/m²). Median preoperative CA-125 levels were 403 U/ml (range: 112-2,115 U/ml). The median performance status of patients (assessed using the ECOG performance status) was 1 (range: 1-2). High grade serous ovarian carcinoma was the most common histological type and was expressed in 11 out of 12 patients (91.7%). Synchronous presence of high grade serous ovarian and endometrioid endometrial carcinoma was detected in one patient whereas another one was diagnosed with ovarian carcinosarcoma as well. At primary diagnosis, 11 (91.7%) patients were classified as FIGO stage IIIC (in double primary cancer patient ovarian was stage IIIC and endometrial IA), whereas the remaining one with carcinosarcoma had FIGO stage IV disease. Ascites was preoperatively detected in 11 (91.7%) cases while 1 patient had also unilateral pleural effusion. Table I depicts baseline patient characteristics.

Short-term outcomes. Six patients (50%) had primary debulking surgery whereas the remaining 6 (50%) underwent interval debulking surgery after 3 cycles of neoadjuvant chemotherapy (NACT) with carboplatin-paclitaxel. All patients were treated with hysterectomy, bilateral salpingo-oophorectomy and omentectomy. In 5 patients (41.6%) peritonectomy was performed in addition to diaphragmatic stripping. Three (25%) patients had splenectomy and one had additional appendicectomy (8.3%). All patients underwent resection of the peritoneum of the right diaphragm while 2 of them (16.6%) had also stripping of the left diaphragmatic peritoneum. Diaphragmatic lesions were the main ablated areas while J-plasma was also applied for the resection of peritoneal mesenteric and liver implants in 5/12 patients (41.6%). Diaphragmatic stripping was applied in 8/12 patients (66.6%), full-thickness resection in 3/12 patients (25%) while in one patient (8.33%) ablation of the diaphragmatic lesions was performed. Five (41.6%)

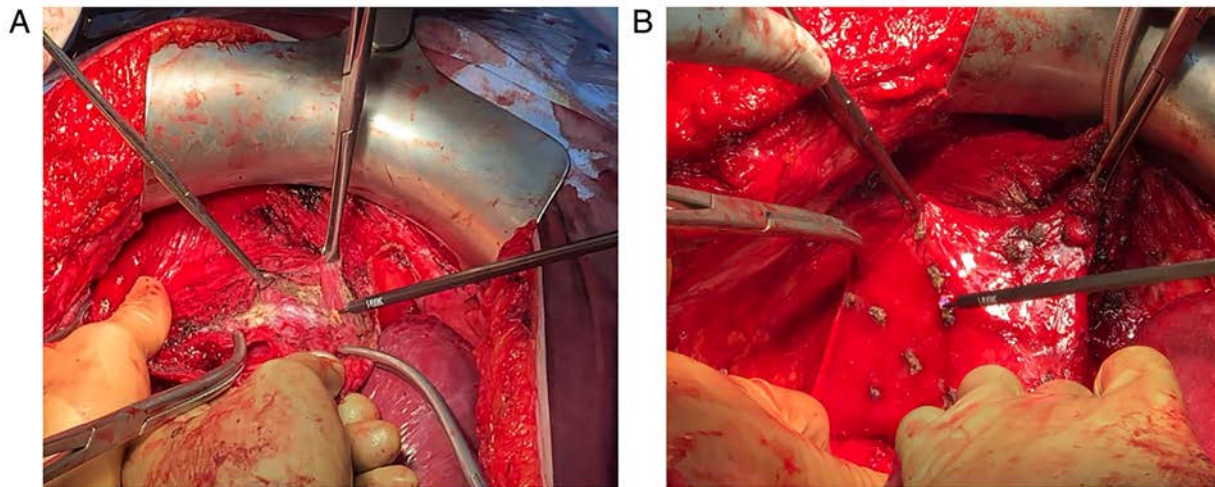


Figure 1. (A) Resection of the diaphragmatic peritoneum of the right hemi-diaphragm with the use of J-Plasma. (B) Ablation of diaphragmatic implants with the use of J-Plasma

patients had concomitant bowel resections due to colorectal involvement. Complete cytoreduction (RD: 0) was achieved in all 12 patients.

Median operative time was 240 min (range: 200-320 min) while the median estimated blood loss was 400 ml (range: 320-1,500 ml). Median operative time for the diaphragmatic resection was 25 min (range: 20-40 min). No major intraoperative complications were recorded except a case of intraoperative hemorrhage which was successfully managed with intraoperative fluid replacement, colloids and blood transfusion. No J-plasma related complications and/or respiratory complications were noted. No defect in the diaphragmatic integrity and connection with the pleural cavity following resection were detected as evaluated by the 'bubble test'. Grade I postoperative complications were detected in 8 patients (66.6%), grade II in 2 (16.7%) patients and grade III complications were recorded in 2 patients (16.7%) (Table II). Median length of hospital stay was 9.5 days (range: 7-20 days). No postoperative mortality was recorded. Table II depicts the short term surgical outcomes.

Survival outcomes. Postoperatively, 6 patients that received NACT, were treated with 3 cycles of adjuvant chemotherapy using carboplatin-paclitaxel whilst the remaining 6 patients received 6 cycles of carboplatin-paclitaxel. During a median follow-up period of 12 months (range: 6-26 months), 2 patients (17%) presented with a disease recurrence (one local pelvic wall recurrence and one distant peritoneal) while none of the patients died of the disease during the follow-up period. Median disease free survival was 12 months (range: 10-13 months) (Table II).

Discussion

In the present study we sought to evaluate the safety and efficacy of a novel device in terms of resection of diaphragmatic lesions in patients with disseminated advanced OC with diaphragmatic involvement. Based on the currently available literature, this is to the best of our knowledge, the first study which evaluated the potential effect of helium gas cold

atmospheric plasma with the use of J-plasma electro-surgical device for the management of peritoneal carcinomatosis due to epithelial OC. In our study the device was primarily used during diaphragmatic stripping of peritoneal metastases. We observed that J-plasma effectively allowed complete resection of peritoneal lesions with low impact on postoperative morbidity. Moreover, none of the patients experienced recurrence in the site of lesions treated with J-plasma; thus, depicting its potential treatment efficacy in controlling the disease, at least during the first year following primary debulking surgery.

The application of J-Plasma is based on the combination of radiofrequency power with the cold flow of helium gas. The most important feature of the device is the minimal depth of diffusion of energy into the adjacent tissues, compared to other known energy technologies (15). Consequently, the respective damage to the remaining healthy tissue is limited. This important feature of J-Plasma technology makes the device suitable for a plethora of applications and more specifically, for the destruction or resection of various malignant lesions in areas requiring subtle manipulations. Moreover, the effect of the CAP component (Cold Atmospheric Plasma), provides the unique ability of selective destruction of various types of cancer and bacterial cells (16). The energy that is released by the CAP component of J-Plasma, has proved to interact individually or in combination with tissues biological cells. Research on this novel observation has highlighted the benefits of CAP in a number of therapeutic and cosmetic applications (17). To that end, ongoing research in this field seems promising in establishing new medical applications for cold plasma. J-Plasma is the energy source that harnesses the benefits of CAP in surgery for open, laparoscopic and robotic surgical procedures.

In clinical practice, the pilot application of J-Plasma during surgery for gynecological diseases has also been described for the treatment of endometriosis with encouraging outcomes in terms of damage to the underlying tissues (17). However, those are still preliminary outcomes and further studies are needed so as to designate the exact depth of spread to the surrounding tissues as well as the impact of this energy source in ovarian reserve.

Table I. Baseline patient characteristics.

Characteristic	Value
Median age, years (range)	65 (45-75)
Median BMI, kg/m ² (range)	27 (23-32)
ECOG performance status	1 (1-2)
Median CA-125 (U/ml)	403 (112-2115)
Histological type, n (%)	
High grade serous	10 (83.4%)
Serous high grade + endometrioid endometrial	1 (8.3%)
Carcinosarcoma	1 (8.3%)
FIGO stage, n (%)	
IIIC	11 (91.7%) ^a
IV	1 (8.3%)
Ascites, n (%)	11 (91.7%)
Pleural effusion, n (%)	1 (8.3%)

^aIn the patient with double primary OC and EC cancer, OC was staged as IIIC and EC was IA staged according to FIGO classification. ECOG, Eastern Cooperative Oncology Group; CA-125, mucin 16; FIGO, International Federation of Gynecology and Obstetrics; OC, ovarian cancer; EC, endometrial

Given the fact that OC disseminates through the peritoneum surface, electrosurgical ablative methods and techniques with minimal penetration to the underlying tissue could be beneficial ensuring a lower morbidity as well as eradication of lesions identified in surgically demanding locations (9). Various types of energy sources such as monopolar ablation, CO₂ laser, argon beam plasma and plasma energy, have been proposed aiming at the complete resection of the malignant lesions while simultaneously reducing the lateral spread and penetration to the affected organs (18-20).

Despite the high prevalence of diaphragmatic involvement in cases of advanced OC with involvement of the upper abdomen, diaphragmatic resection is technically challenging and is performed by less than 30% of the gynecologic oncologists in the UK, precluding thus complete cytoreduction in these patients (12). Moreover, Eskander *et al* have showed that ~39% of the patients with advanced OC reported to have undergone optimal cytoreduction, still have disease on the right and left diaphragmatic area (21). A plethora of less invasive techniques have reported favorable outcomes in the treatment of diaphragmatic implants including peritoneal stripping, radio-frequency ablation and argon beam plasma ablation (8,22). In the present study, we sought to apply J-Plasma as a minimal invasive electrosurgical method for resection of diaphragmatic implants and peritoneal lesions. The median operative time for the diaphragmatic resection of 20 min, including the application of the technique was comparable to those reported by other studies reporting outcomes of various diaphragmatic interventions (22,23). Among them, Muallem *et al* reported a significantly prolonged operative time in patients who had diaphragmatic surgery compared to those who had cytoreductive procedures without diaphragmatic resection, which could

Table II. Short- and long-term perioperative outcomes.

Outcome	No. of patients (%)
Type of debulking surgery	
PDS, n (%)	6 (50)
IDS, n (%)	6 (50)
Type of surgical procedure, n (%)	
TAH/BSO	12 (100)
Omentectomy	12 (100)
Peritonectomy	5 (41.6)
Splenectomy/Appendectomy	3 (25)/1 (8.33)
Bowel resection	5 (41.6)
Right diaphragmatectomy	12 (100)
Left diaphragm stripping	2 (16.6)
Median operative time, min (range)	240 (200-320)
Median estimated blood loss, ml (range)	600 (320-1500)
Median length of hospital stay, days (range)	9.5 (7-20)
Complications, n (%)	
Nausea and vomiting	3 (25)
Fever	1 (8.3)
Surgical site infection	2 (16.7)
Anemia	2 (16.7)
Ileus	1 (8.3)
Intra-abdominal abscess	2 (16.7)
Cardiac ischemia	1 (8.3)
Complications (Dindo-Clavien), n (%)	
I	8 (66.6)
II	2 (16.7)
III	2 (16.7)
30 day mortality, n	0
Recurrences, n (%)	2 (17)
Median OS, months (range)	12 (6-26)
Median DFS (months)	12 (10-13)

PDS, primary debulking surgery; IDS, interval debulking surgery; TAH/BSO, total abdominal hysterectomy and bilateral salpingo-oophorectomy; DFS, disease-free survival; OS, overall survival.

probably be attributed to the surgically demanding diaphragmatic areas as well as to the operative technique (22). In the same study, the mean difference in operative time among procedures, which include diaphragmatic resection and those, which did not, was 38.5 min which was approximately double as much as that of diaphragmatic resection found in our study (21 min). This could indicate the potential beneficial effect of J-Plasma in minimizing the time of diaphragmatic resection based on its ability to simultaneous coagulate the small vessels that require coagulation. Overall, ~2/3 of our patients required diaphragmatic stripping for the management of the disease while full-thickness resection was performed in one fourth of them. Those rates are in accordance to those reported in the literature for diaphragmatic resection techniques (22).

Compared to full-thickness diaphragmatic excision it has been proved that performing only peritoneal diaphragmatic stripping has been associated with significantly decreased pulmonary complication rates (33-72.7 vs. 19.5-46.6%, respectively) (13). In the present study, we did not record any pulmonary complications not even in the patients who underwent full-thickness diaphragmatic excisions.

Despite J-Plasma's promising effect, our results should be interpreted as preliminary as our study primarily aimed at evaluating short term complications of J-plasma and not its treatment efficacy. The small-sample size, the short follow-up period and the retrospective nature of the present study are considered the main limitations of our study. However, future randomized trials should be organized with an adequate follow-up time which will permit extraction of safe conclusions concerning the impact of J-plasma on long-term control of treated metastases and evaluation of patterns of relapse in these patients.

Concluding, the findings of our study support that J-plasma can be used during diaphragmatic stripping as it is associated with low rates of short-term morbidity and less operative time needed for stripping which are lower compared to the one that follows traditional peritoneal technic. Furthermore, in terms of disease control it seems to be particularly effective as none of our patients experienced disease relapse in abdominal regions that were treated with J-plasma. However, given the absence of a control group and the lack of an adequate follow-up time its effect on the long term survival of OC patients undergoing debulking operations remains elusive.

Acknowledgements

The abstract was presented in the 27th European Congress of Obstetrics and Gynaecology Sep 2-4 2021 in Athens, Greece and published as abstract no. 410 in Eur J Obstet Gynecol Reprod Biol 270 (e109-e110): Mar 2022.

Funding

No funding was received.

Availability of data and materials

The datasets used and/or analyzed during the current study are available from the corresponding author on reasonable request.

Authors' contributions

DH conceived, supervised and validated the study and methodology, performed investigation, supervised and wrote, reviewed and edited the original draft. VT analyzed and curated the data, obtained resources and wrote the original draft. AP analyzed and curated the data, performed investigation, designed methodology, obtained resources and wrote the original draft. ES performed investigation, visualized the data and wrote and reviewed the original draft. NA interpreted the data, wrote and reviewed the original draft. AR conceived, designed, supervised the study and reviewed and edited the original draft. All authors have read and approved the final

manuscript. VT and AP confirm the authenticity of all the raw data.

Ethics approval and consent to participate

This retrospective chart review study involving human participants was in accordance with the ethical standards of the institutional and national research committee and with the 1964 Helsinki Declaration and its later amendments or comparable ethical standards. The Human Investigation Committee (IRB) of General Hospital 'Alexandra' approved this study (approval no. 800/14-10-2019).

Patient consent for publication

Not applicable.

Competing interests

The authors declare that they have no competing interests.

References

1. Siegel RL, Miller KD and Jemal A: Cancer statistics, 2019. *CA Cancer J Clin* 69: 7-34, 2019.
2. Baek MH, Lee SW, Park JY, Rhim CC, Kim DY, Suh DS, Kim JH, Kim YM, Kim YT and Nam JH: Preoperative predictive factors for complete cytoreduction and survival outcome in epithelial ovarian, tubal, and peritoneal cancer after neoadjuvant chemotherapy. *Int J Gynecol Cancer* 27: 420-429, 2017.
3. Rehmani H, Li Y, Li T, Padia R, Calbay O, Jin L, Chen H and Huang S: Addiction to protein kinase Ct due to PRKCI gene amplification can be exploited for an aptamer-based targeted therapy in ovarian cancer. *Signal Transduct Target Ther* 5: 140, 2020.
4. Liang MI, Prendergast EN, Staples JN, Holschneider CH, Cohen JG and Cass I: Prognostic role of pathologic response and cytoreductive status at interval debulking surgery after neoadjuvant chemotherapy for advanced epithelial ovarian cancer. *J Surg Oncol* 120: 779-785, 2019.
5. Eggink FA, Koopmans CM and Nijman HW: Surgery for patients with newly diagnosed advanced ovarian cancer: Which patient, when and extent? *Curr Opin Oncol* 29: 351-358, 2017.
6. Kim SI, Hwang WY, Lee M, Kim HS, Kim K, Chung HH, No JH, Kim JW, Kim YB, Park NH, *et al*: Survival impact of extended cycles of second-line chemotherapy in platinum-sensitive relapsed ovarian cancer patients with residual tumor after six cycles. *BMC Cancer* 20: 1199, 2020.
7. Lindemann K, Gao B, Mapagu C, Fereday S, Emmanuel C, Alsop K, Traficante N, Australian Ovarian Cancer Study Group; Harnett PR, Bowtell DDL and deFazio A: Response rates to second-line platinum-based therapy in ovarian cancer patients challenge the clinical definition of platinum resistance. *Gynecol Oncol* 150: 239-246, 2018.
8. Bacalbasa N, Balescu I, Balalau C, Ionescu O and Stoica C: Association of diaphragmatic surgery as part of cytoreductive effort in advanced stage ovarian cancer. *In Vivo* 32: 431-436, 2018.
9. Pounds R, Phillips A, Kehoe S, Nevin J, Sundar S, Elattar A, Teo HG, Singh K and Balega J: Diaphragm disease in advanced ovarian cancer: Predictability of pre-operative imaging and safety of surgical intervention. *Eur J Obstet Gynecol Reprod Biol* 226: 47-53, 2018.
10. Grimm C, Harter P, Heitz F and du Bois A: The sandwich technique of diaphragmatic stripping or full-thickness resection for advanced ovarian cancer: How to keep it short and simple. *Int J Gynecol Cancer* 25: 131-134, 2015.
11. Majd HS, Ferrari F, Manek S, Gubbala K, Campanile RG, Hardern K and Tozzi R: Diaphragmatic peritonectomy vs. full thickness resection with pleurectomy during visceral-peritoneal debulking (VPD) in 100 consecutive patients with stage IIIC-IV ovarian cancer: A surgical-histological analysis. *Gynecol Oncol* 140: 430-435, 2016.

12. Panuccio E, Leunen K, Van Nieuwenhuysen E, Neven P, Lambrechts S and Vergote I: Use of plasmajet for peritoneal carcinomatosis in ovarian cancer. *Int J Gynecol Cancer* 26: 1521-1524, 2016.
13. Kehoe SM, Eisenhauer EL and Chi DS: Upper abdominal surgical procedures: Liver mobilization and diaphragm peritonectomy/resection, splenectomy, and distal pancreatectomy. *Gynecol Oncol* 111 (Suppl 2): S51-S55, 2008.
14. Prat J; FIGO Committee on Gynecologic Oncology: Staging classification for cancer of the ovary, fallopian tube, and peritoneum. *Int J Gynaecol Obstet* 124: 1-5, 2014.
15. Oken MM, Creech RH, Tormey DC Horton J, Davis TE, McFadden ET and Carbone PP: Toxicity and response criteria of the eastern cooperative oncology group. *Am J Clin Oncol* 5: 649-656, 1982.
16. Dindo D, Demartines N and Clavien PA: Classification of surgical complications: A new proposal with evaluation in a cohort of 6336 patients and results of a survey. *Ann Sur* 240: 205-213, 2004.
17. Parsa M: Retroperitoneal dissection of ovarian endometrioma using J-Plasma technology. *J Minim Invasive Gynecol* 22: S140, 2015.
18. Renaud MC and Sebastianelli A: Optimal cytoreduction with neutral argon plasma energy in selected patients with ovarian and primitive peritoneal cancer. *J Obstet Gynaecol Can* 35: 49-52, 2013.
19. Sonoda Y, Olvera N, Chi DS, Brown CL, Abu-Rustum NR and Levine DA: Pathologic analysis of ex vivo plasma energy tumor destruction in patients with ovarian or peritoneal cancer. *Int J Gynecol Cancer* 20: 1326-1330, 2010.
20. Prodromidou A, Pandraklakis A and Iavazzo C: The emerging role of neutral argon plasma (PlasmaJet) in the treatment of advanced stage ovarian cancer: A systematic review. *Surg Innov* 27: 299-306, 2020.
21. Eskander RN, Kauderer J, Tewari KS, Mannel RS, Bristow RE, O'Malley DM, Rubin SC, Glaser GE, Hamilton CA, Fujiwara K, *et al*: Correlation between Surgeon's assessment and radiographic evaluation of residual disease in women with advanced stage ovarian cancer reported to have undergone optimal surgical cytoreduction: An NRG oncology/gynecologic oncology group study. *Gynecol Oncol* 149: 525-530, 2018.
22. Muallem MZ, Almuheimid J, Richter R, Braicu EI, Osman S and Sehouli J: Diaphragmatic surgery in advanced ovarian, tubal and peritoneal cancer. A 7-year retrospective analysis of the tumor bank ovarian cancer network. *Anticancer Res* 36: 4707-4713, 2016.
23. Tsolakidis D, Amant F, Van Gorp T, Leunen K, Neven P and Vergote I: Diaphragmatic surgery during primary debulking in 89 patients with stage IIIB-IV epithelial ovarian cancer. *Gynecol Oncol* 116: 489-496, 2010.